

Case 4

This “Case” is actually a series of cases. You are the physiatrist in the Plexopathy clinic today. You have 4 patients to see. There are 13 questions to answer.

Patient 1

Mr A. is a healthy 52yo male. He comes to your clinic because he has trouble with his left hand. He has difficulty defining it but says it feels “strange” and doesn’t “react like usual”.

1. **Just with this information, what would be your differential diagnosis?**

Discuss as a group, and when ready, go to the next question.

After taking the history and completing the physical examination, your principal diagnosis is **carpal tunnel syndrome**.

2. **What studies do you plan to perform in the Neurophysiologic/Electromyography lab?**

Discuss as a group, and when ready, go to the next question.

3. **You are training a new technologist in the clinic. Explain how you grade the severity of Carpal Tunnel Syndrome.**

Discuss as a group and when ready go to the next question

4. **What is your care plan for moderate Carpal Tunnel Syndrome?**

Discuss as a group and when ready go to the next question

5. **What would be your differential diagnosis if you have a normal Median sensory nerve action potential (SNAP) with an absent thenar compound muscle action potential (CMAP)?**

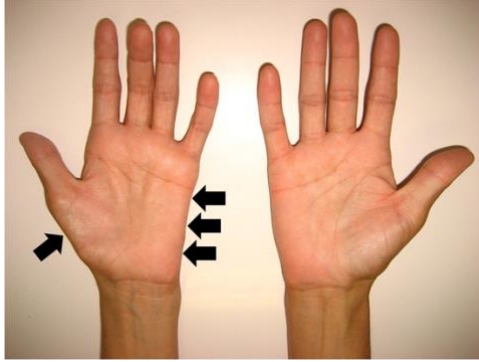
Discuss as a group and when ready go to the next question

6. **What would be your primary diagnosis if the first dorsal interosseous (FDI) and the thenar were wasted, but the abductor digiti minimi (ADM) was preserved?**

Discuss as a group and when ready go to the next question

7. **On the other hand, what would be your main diagnosis if the thenar eminence and abductor digiti mini (ADM) were affected much more than the first dorsal interosseous (FD); also called Gilliat-Sumner hand?**

Case 4



Discuss as a group and when ready go to the next question

Patient 2

8. Ms. C is referred to your clinic for a suspected C7 radiculopathy. What muscles would you test in the needle EMG?

Discuss as a group and when ready go to the next question

Patient 3

Mr. D is coming to your clinic because he has had weakness in his left arm for the last few months. He has a history of lung cancer treated with radiotherapy. You are trying to remember the differences between neoplasia recurrence and radiation plexopathy.

9. Fill out the table below.

	Neoplastic	Radiation
Associated conditions		
Common presentation		
Progression		
Electrodiagnostic findings (and how you would test this?)		

Discuss as a group and when ready go to the next question

Case 4

Patient 4

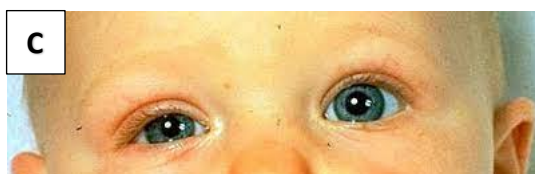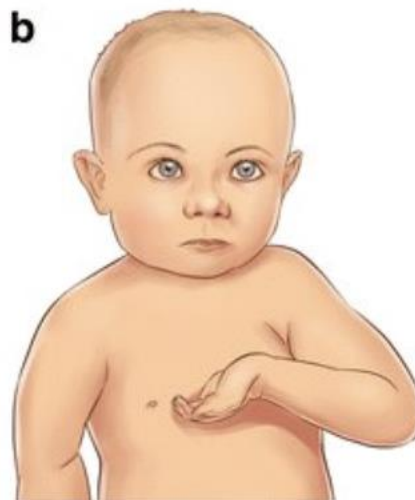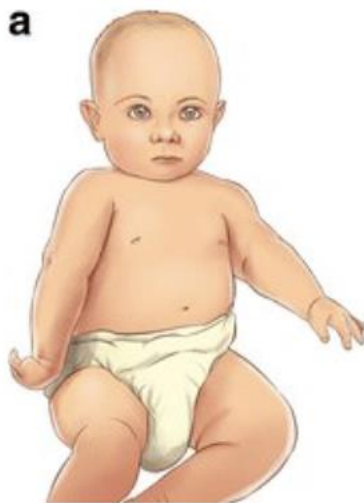Baby B is a 1-month-old, accompanied by her parents. They have noticed that her right arm is not moving like her left arm. You suspect a neonatal brachial plexus palsy.

10. What questions would you ask on history to determine the cause?

Discuss as a group and when ready go to the next question

11. Looking at the following different pictures, what is the localization of the lesion (and give the name of the condition if there is one)?

Discuss as a group and when ready go to the next question



Case 4

- 12. What are the important elements to look for in the Neurophysiologic/Electromyography (EMG) lab for the prognosis (electrodiagnostic + clinical)?**

Discuss as a group and when ready go to the next question

- 13. During the appointment, you sense tension between the parents. After receiving the follow-up date, while the father is in the bathroom, the mother comes back to ask for another date and says she doesn't want the father to know it.**

How will you respond?

Be prepared to share your answers with the larger group