



# Proteus Syndrome: Right Lower Extremity Deformity

**David Westberry, MD**

---

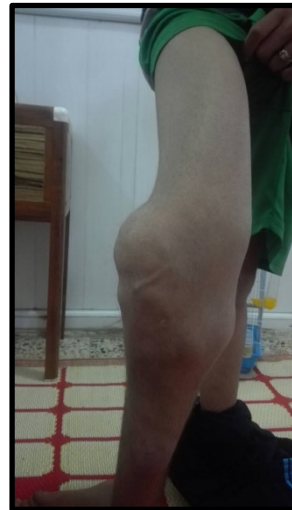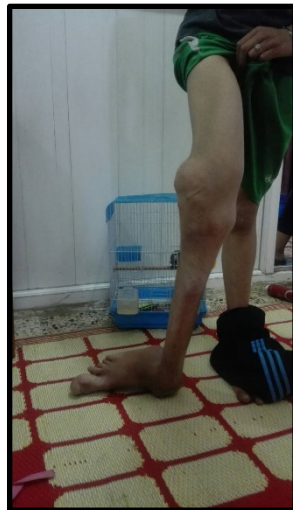

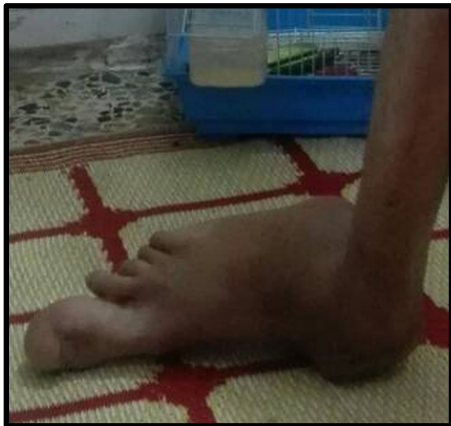
**Shriners Hospitals**  
for Children®— Greenville



# Case History

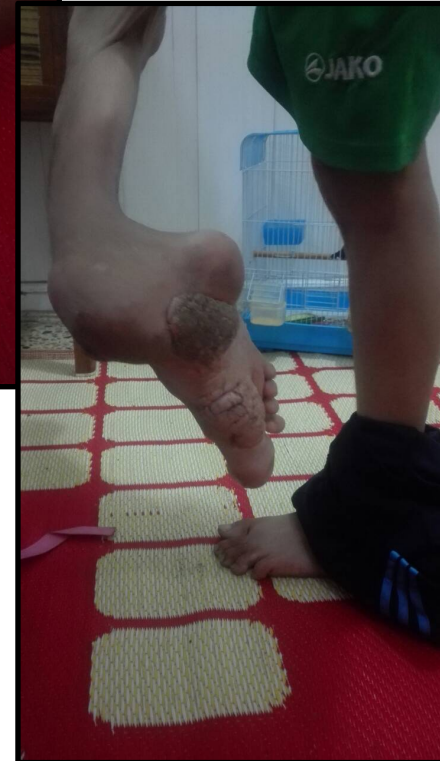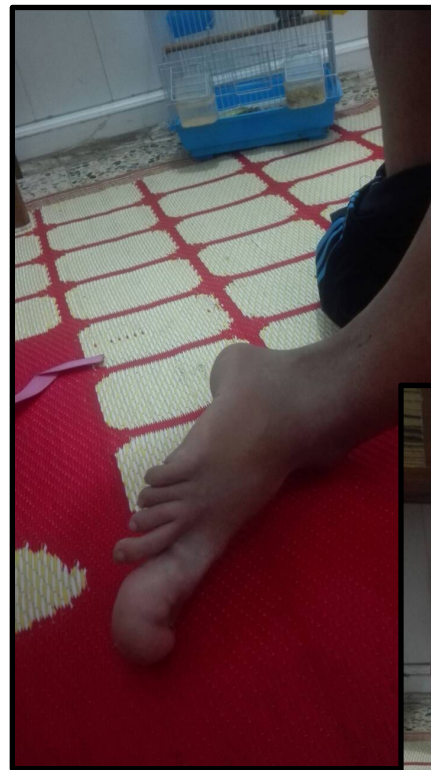
- **16 year old male**
  - Right LE deformity noted at birth
  - Progression of deformity through childhood
  - Resides in Middle East





# Case History

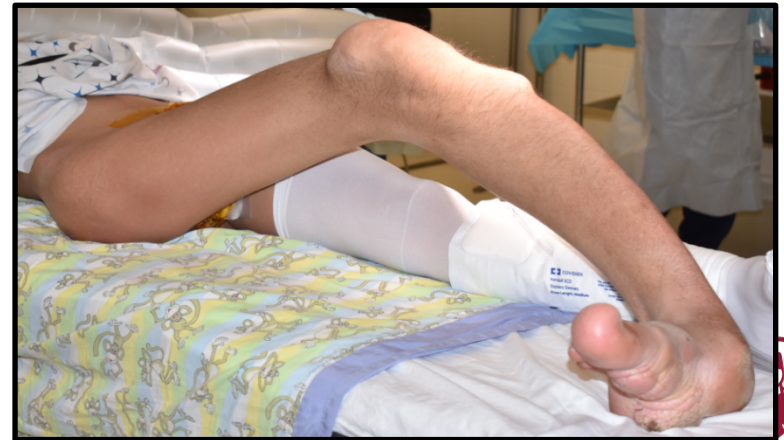- **6 years of age**
- **Amputation recommended**
  - Taken to operating room in Iraq, but dismissed after hours long wait without treatment
  - No other treatment attempted
- **Increased deformity leading to functional and societal challenges**





# Clinical Presentation

- External foot progression angle
- Right foot deformity
  - Enlarged right great toe and medial border
  - Severe pronation
- Anterior medial bowing of tibia
- Knee flexion contracture
- Knee ROM 20-40 degrees
- Patella enlargement
- Medial bowing of right femur
- External rotation contracture of right hip

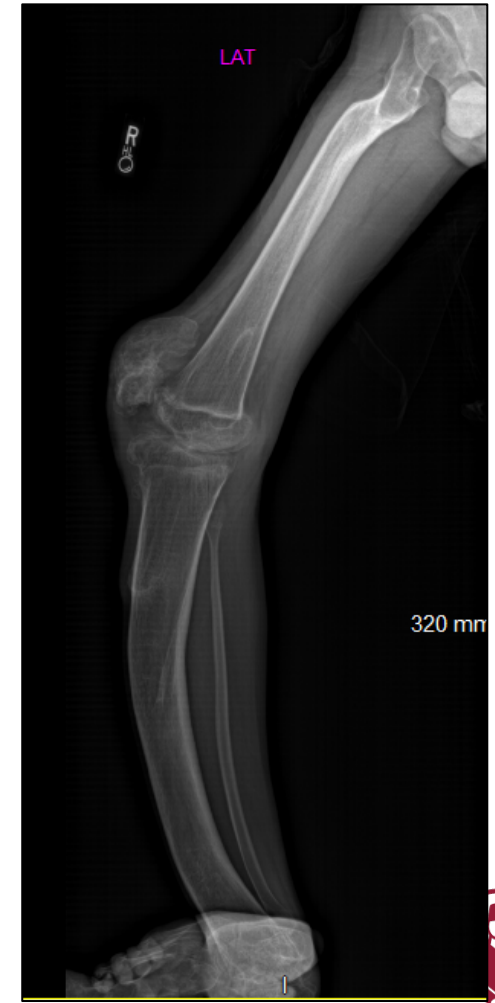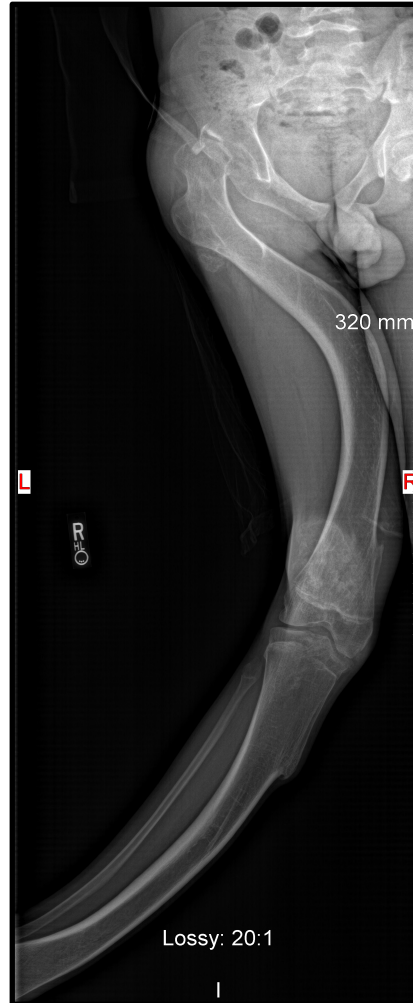






# Radiographic Findings

- **Right hip**
  - Mild dysplasia
- **Right femur**
  - Medial bow
- **Right tibia**
  - Anterior medial bow
- **Patella**
  - Hyperplasia





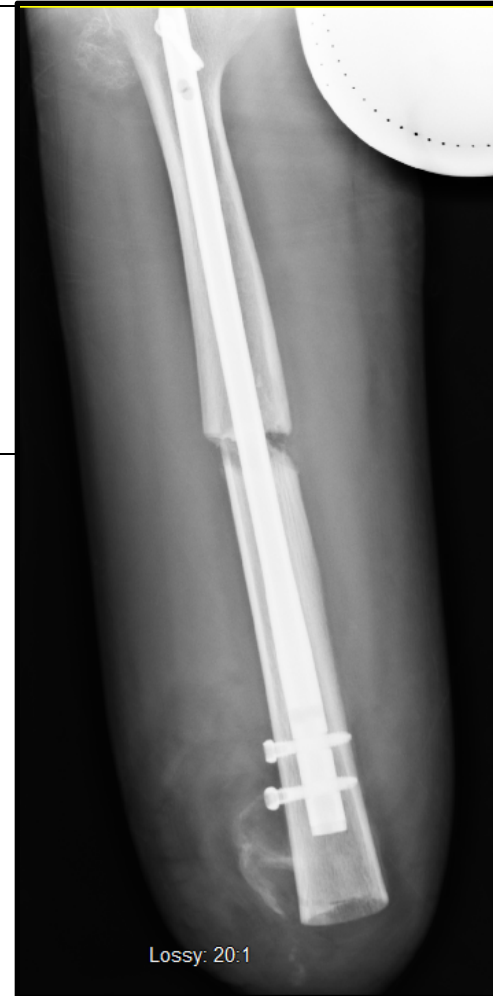
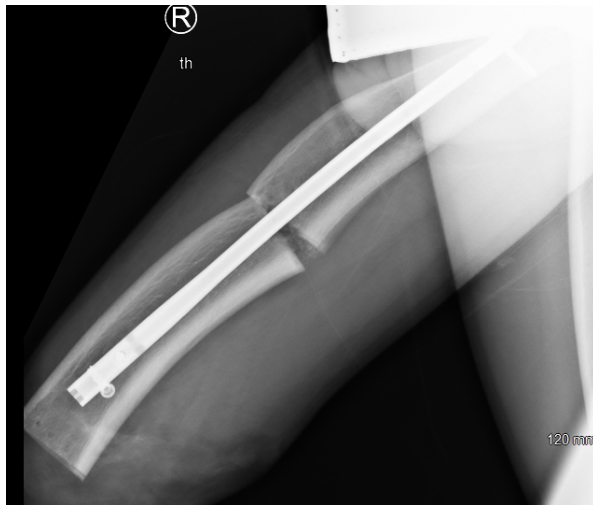
- **Treatment options?**





# Recommendation for Treatment

- Right above knee amputation
- Patellectomy
- Femoral osteotomy with retrograde femoral nail





# Postoperative Results

- **Patient happy with results**
- **Mild phantom pain**
  - Medical management
- **Returned home after several weeks in physical therapy with host family**



